

**U.S. ARMY MEDICAL DEPARTMENT CENTER AND SCHOOL
FORT SAM HOUSTON, TEXAS 78234-6100**



CHEST AND AIRWAY PROBLEMS

SUBCOURSE MD0569 EDITION 100

DEVELOPMENT

This subcourse is approved for resident and correspondence course instruction. It reflects the current thought of the Academy of Health Sciences and conforms to printed Department of the Army doctrine as closely as currently possible. Development and progress render such doctrine continuously subject to change.

The subject matter expert responsible for content accuracy of this edition was the NCOIC, Nursing Science Division, DSN 471-3086 or area code (210) 221-3086, M6 Branch, Academy of Health Sciences, ATTN: MCCS-HNP, Fort Sam Houston, Texas 78234-6100.

ADMINISTRATION

Students who desire credit hours for this correspondence subcourse must meet eligibility requirements and must enroll in the subcourse. Application for enrollment should be made at the Internet website: <http://www.atrrs.army.mil>. You can access the course catalog in the upper right corner. Enter School Code 555 for medical correspondence courses. Copy down the course number and title. To apply for enrollment, return to the main ATRRS screen and scroll down the right side for ATRRS Channels. Click on SELF DEVELOPMENT to open the application and then follow the on screen instructions.

For comments or questions regarding enrollment, student records, or examination shipments, contact the Nonresident Instruction Branch at DSN 471-5877, commercial (210) 221-5877, toll-free 1-800-344-2380; fax: 210-221-4012 or DSN 471-4012, e-mail accp@amedd.army.mil, or write to:

NONRESIDENT INSTRUCTION BRANCH
AMEDDC&S
ATTN: MCCS-HSN
2105 11TH STREET SUITE 4191
FORT SAM HOUSTON TX 78234-5064

CLARIFICATION OF TERMINOLOGY

When used in this publication, words such as "he," "him," "his," and "men" are intended to include both the masculine and feminine genders, unless specifically stated otherwise or when obvious in context.

TABLE OF CONTENTS

<u>Lesson</u>		<u>Paragraphs</u>
	INTRODUCTION	
1	CHEST TRAUMA	
	Section I General Information About Chest injuries.	1-1--1-5
	Section II Specific Chest Injuries.....	1-6--1-13
	Section III Chest Decompression.....	1-14--1-16
	Exercises	
2	AIRWAY MANAGEMENT	
	Section I Esophageal Obturator Airway	2-1--2-6
	Section II Endotracheal Tube.....	2-7--2-13
	Exercises	
3	CRICOTHYROIDOTOMY	
	Section I General Considerations	3-1--3-4
	Section II Needle Cricothyroidotomy.....	3-5--3-6
	Section III Surgical Cricothyroidotomy	3-7--3-9
	Exercises	

**CORRESPONDENCE COURSE OF
THE U.S. ARMY MEDICAL DEPARTMENT CENTER AND SCHOOL
SUBCOURSE MD0569
CHEST AND AIRWAY PROBLEMS**

INTRODUCTION

In this subcourse, you will study chest and airway problems. Chest trauma refers to general information about chest injuries as well as information about specific chest injuries. Airway problems includes information on devices--the esophageal obturator airway (EOA), the esophageal gastric tube airway (EGTA), and the endotracheal tube (ET)--that can be used to open and maintain an airway. If other life-saving methods are not successful in opening and maintaining an airway, an opening is made in the trachea to bypass the site of an upper airway obstruction. This subject matter is of vital importance in saving lives.

Subcourse Components:

The subcourse instructional material consists of four lessons as follows:

- Lesson 1, Chest Trauma.
- Lesson 2, Airway Management.
- Lesson 3, Cricothyroidotomy.

Here are some suggestions that may be helpful to you in completing this subcourse:

- Read and study each lesson carefully.
- Complete the subcourse lesson by lesson. After completing each lesson, work the exercises at the end of the lesson, marking your answers in this booklet.
- After completing each set of lesson exercises, compare your answers with those on the solution sheet that follows the exercises. If you have answered an exercise incorrectly, check the reference cited after the answer on the solution sheet to determine why your response was not the correct one.

Credit Awarded:

Upon successful completion of the examination for this subcourse, you will be awarded 8 credit hours.

To receive credit hours, you must be officially enrolled and complete an examination furnished by the Nonresident Instruction Branch at Fort Sam Houston, Texas.

You can enroll by going to the web site <http://atrrs.army.mil> and enrolling under "Self Development" (School Code 555).

A listing of correspondence courses and subcourses available through the Nonresident Instruction Section is found in Chapter 4 of DA Pamphlet 350-59, Army Correspondence Course Program Catalog. The DA PAM is available at the following website: <http://www.usapa.army.mil/pdffiles/p350-59.pdf>.

LESSON ASSIGNMENT

LESSON 1

Chest Trauma

LESSON ASSIGNMENT

Paragraphs 1-1 through 1-16.

LESSON OBJECTIVES

After completing this lesson, you should be able to:

1-1. Identify common signs, common treatment, and general principles of treatment for chest injuries.

1-2. Define these specific chest injuries and identify the signs/symptoms and treatment of the specific chest injuries:

Fractured ribs or sternum.

Flail chest.

Cardiac contusion.

Hemothorax.

Simple pneumothorax.

Subcutaneous emphysema.

Open pneumothorax.

Tension pneumothorax.

1-3. List the steps in the procedure of two types of chest decompression (needle chest decompression and catheter -over-needle chest decompression) in the order of performance.

SUGGESTION

After completing the assignment, complete the exercises of this lesson. These exercises will help you to achieve the lesson objectives.

LESSON 1

CHEST TRAUMA

Section I. GENERAL INFORMATION ABOUT CHEST INJURIES

1-1. INTRODUCTION

Chest injuries are of major importance because they are a common cause of death. Fifty percent of the people who expire from chest injuries die on the way to the hospital. The common causes of penetrating and nonpenetrating chest injuries include automobile accidents, falls and blows, gunshot wounds, stab wounds, and crushing injuries. In a chest injury, there is a possibility of internal bleeding and/or direct injury to the heart or lungs; therefore, any chest injury may be serious. Chest decompressions, field functions, and other procedures may be used to save the casualty's life if they are performed correctly and in a timely manner. With specialized training and prescribed methods of treatment for various chest trauma, your ability to recognize and react quickly in each situation is an important factor in regard to whether the casualty survives.

1-2. COMMON SIGNS/SYMPTOMS OF CHEST INJURIES

The common signs and symptoms of chest injuries are:

- a. A change in normal breathing pattern.
- b. Pain at the site of the injury.
- c. Dyspnea (shortness of breath).
- d. Failure of the chest to expand.
- e. A rapid/weak pulse.
- f. Low blood pressure.
- g. A dry cough or blood.
- h. A sucking sound on respiration.
- i. Cyanosis (bluish discoloration of the skin due to lack of oxygen).
- j. Hemoptysis (spitting of blood from lesions in the larynx, traches, or lower respiratory tract).

1-3. COMMON TREATMENT FOR CHEST INJURIES

Regardless of the type of chest injury, initial treatment is almost always the same. Begin by examining the casualty to detect the chest injury.

- a. Question the casualty, if he is conscious, to see if he has difficulty in breathing.
- b. Observe the casualty's bare chest and upper abdomen for respiratory rate and depth.
- c. Check for equal movement of both sides of the casualty's chest.
- d. Examine the entire chest wall (including the back) beneath any overlying clothing.
- e. Listen to the casualty's chest with a stethoscope. Listen to both sides of the chest, comparing both sides for volume, loudness, and equality.

1-4. TYPES OF CHEST INJURIES

a. **Penetrating Injuries.** A penetrating injury may be a hole in the thoracic cavity that allows air inside the thorax, the air filling the thoracic cavity (pneumothorax). A penetrating injury may cause blood to flow into the thoracic cavity (hemothorax), filling the thorax with blood.

b. **Blunt Injuries.** These are blunt injuries: rib and sternum damage; flail chest; and cardiac contusion.

c. **Results of Penetrating/Blunt Injuries.** Penetrating and blunt injuries can cause considerable damage. Both types of injury can cause air to build up outside the lung in the thoracic cavity, and the individual has simple pneumothorax. The pressure has not been great enough to cause the lung to collapse. A blunt injury or a penetrating injury may cause air to build up to such great pressure in the thoracic cavity that the lungs collapse. Tension pneumothorax is the name of this condition.

1-5. GENERAL PRINCIPLES OF TREATMENT FOR CHEST TRAUMA

Follow these general principles in treating for chest trauma:

a. Maintain normal pleural pressure by the use of suction devices throughout the treatment. Keep the pleural space empty by using suctioning devices such as hemovac or pleuralvac. Monitor the suctioning device frequently, regardless of which device is used.

b. Monitor the casualty for pericardial tamponade. This condition, which will be discussed later, is caused by penetrating chest wounds such as gunshot wounds or stab wounds. The result of the condition can be diminished cardiac output and finally death; therefore, it is extremely important to watch for signs of pericardial tamponade in the person.

c. Keep the bronchial tree clear of retained blood, foreign material, and bronchial secretions by using suction as needed.

d. Give oxygen to maintain adequate oxygenation and removal of carbon dioxide. If oxygen administered by nasal catheter is inadequate, use tracheal intubation, cricothyroidotomy, or controlled positive breathing.

e. Estimate the amount of hemorrhage the casualty has, and replace the blood as necessary.

Section II. SPECIFIC CHEST INJURIES

1-6. FRACTURED RIBS OR STERNUM

a. **Fractured Ribs.** Fractured ribs are usually caused by blunt, direct blows or compression injuries of the chest. The upper ribs are protected--in front by the clavicle, in back by the scapulae, in the side by the arms, and by the heavy muscles of the upper thorax and its appendages--and are rarely fractured. The fifth through the ninth ribs are most commonly fractured. The lower two ribs are attached to the thoracic vertebrae and have movement; therefore, they are rarely fractured.

b. **Fractured Sternum.** Fracture of the sternum occurs about once in every twenty chest injuries. Sternum are an indication to look for other serious injuries because a blow hard enough to fracture the sternum will often cause serious damage in the thorax. Injuries associated with a fractured sternum include tracheal or bronchial tears, ruptured diaphragm or esophagus, flail chest, and contusion of the myocardium or lung.

c. Signs/Symptoms of Fractured Ribs or Sternum.

(1) Tenderness at the point where the casualty indicates pain.

(2) Pain that worsens when the casualty breathes or coughs.

(3) The casualty may be protecting the affected side by leaning toward that side with his hand protecting it or by splinting the affected side.

(4) Crepitus (grating sounds; sounds which can be heard when bones move against each other).

(5) Subcutaneous emphysema (a condition to be discussed later).

d. Associated Complications.

(1) Rupture or lacerations of underlying structures are common. If there is a direct blow to one or more ribs, there is a possibility that the rib ends may be driven into the lung underneath and the pleura, causing damage.

(2) Internal bleeding may be caused by fractured ribs.

(3) Shock.

e. **Treatment.** Treatment includes examining the casualty for underlying chest problems and giving him something for pain.

1-7. FLAIL CHEST

A flail chest occurs when two or more adjacent ribs are fractured in two or more places resulting in a segment of the thoracic cage becoming detached. Flail chest--also called floating or crushed chest--is more common in today's era of high-speed automobile accidents. It is usually caused by a blunt blow to the ribs. If two or more ribs are broken in two places, the part of the chest wall between the breaks collapses and does not participate in the normal expansion of the chest each time the person inhales. When the casualty exhales, the part of the chest wall between the breaks will protrude while the rest of the chest wall contracts.

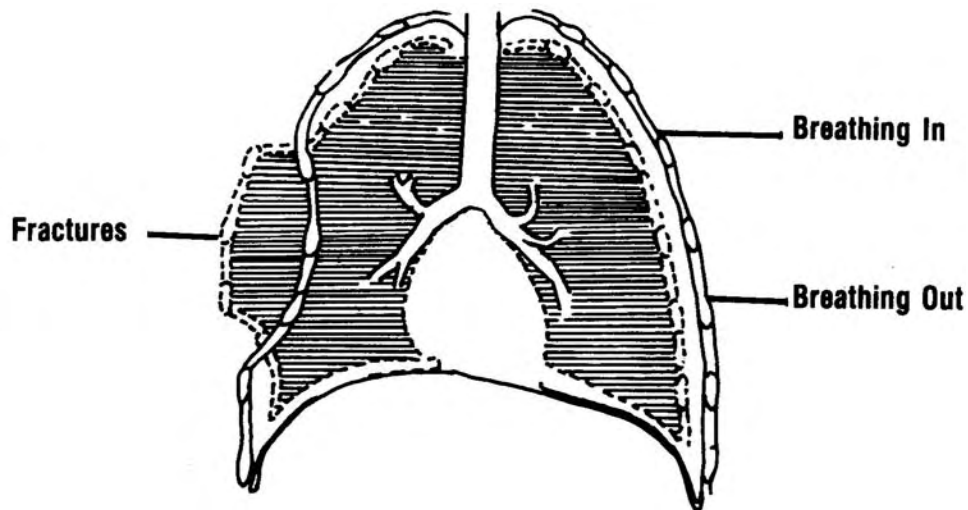


Figure 1-1. Flail chest--paradoxical respirations (active breathing).

a. **Signs/Symptoms.** Signs and symptoms of flail chest include the following:

- (1) Pain at the site of the injury.
- (2) Tachypnea (rapid breathing).
- (3) Paradoxical respirations. For example, the chest expands with expiration (breathing out) and contracts with inhalation (breathing in).

b. **Treatment.** To administer initial treatment to a casualty with a flail chest injury, you should:

- (1) Place your hand, a pillow, or another object on the flail segment to immobilize it.
- (2) Strap or tape the pillow or other object in place.
- (3) Give the casualty oxygen.

1-8. CARDIAC CONTUSION

Cardiac contusion is severe trauma to the anterior chest. This trauma results in bruising and irritation of the heart muscle. This injury is caused by a severe, blunt blow to the chest; for example, a steering wheel injury.

a. **Signs/Symptoms.** Cardiac signs and symptoms include:

- (1) Exposed ribs and/or sternum.
- (2) Cardiac dysrhythmias may be detectable by an irregular pulse. The location of the injury often influences the types of dysrhythmias. An injury to the right side results in atrial dysrhythmias. Injury to the left side or the front results in ventricular dysrhythmias.

b. **Management.** To manage a patient with cardiac contusion, you should:

- (1) Be alert for possible cardiac arrest.
- (2) Help the casualty avoid movement and conditions which could cause a change in heart rate.
- (3) Stabilize the patient and evacuate immediately.

c. **Complication--Cardiac Tamponade.**

(1) Cardiac tamponade. Cardiac tamponade, complication of cardiac contusion, is a condition in which blood or other fluid which has leaked out of the heart in the chest injury is caught in the pericardial sac. The fluid accumulates and compresses the heart so that the chambers of the heart can't hold the blood normally returned to it. This situation must be corrected immediately.

(2) Signs/symptoms of cardiac tamponade.

- (a) Thready, rapid pulse.
- (b) Converging systolic/diastolic blood pressure. (Upper and lower blood pressure readings come closer and closer together as successive readings are taken.)
- (c) Distended neck veins.
- (d) Muffled heart sounds.
- (e) Cool, pale, and clammy skin.
- (f) Death may result, due to inadequate cardiac output.

1-9. **HEMOTHORAX**

Hemothorax is hemorrhaging within the thorax due to the rupture of blood vessels in the chest. The chest is filled up with something other than the lungs. The result is that the lungs cannot expand normally. The casualty is not able to inhale as much air, and there may be less blood to carry this reduced amount of oxygen through the casualty's body. A common cause of hemothorax is a penetrating object to the chest.

a. **Signs/Symptoms of Hemothorax.** Signs and symptoms include the following:

- (1) Respiratory difficulty such as dyspnea or gasping respiration.
- (2) Decreased, absent, or hyporesonance (dull) respiratory sound.

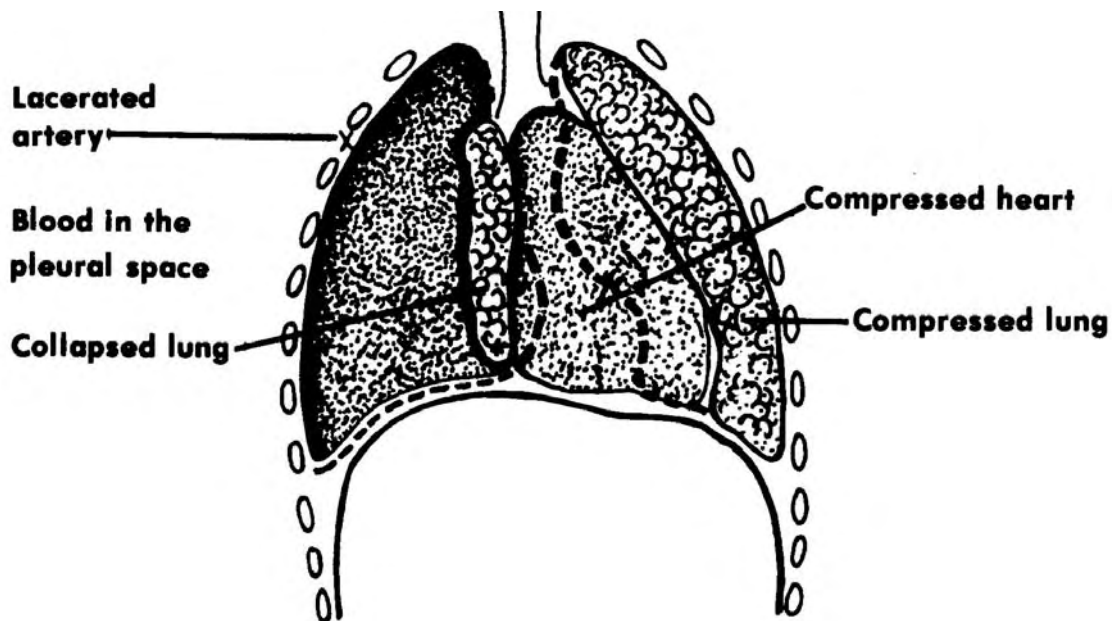


Figure 1-2. Hemothorax.

(3) Early and severe signs of hypovolemia (abnormally diminished volume of blood circulating in the body) and shock to include:

- (a) Loss of up to three liters of blood, possibly in a short period of time.
 - (b) Low blood pressure.
 - (c) Increased heart rate.
- (4) A chest x-ray will show:
- (a) Collapse of a lung.
 - (b) Fluid in the pleural space.

b. **Treatment for Hemothorax.** To treat for hemothorax, you should:

- (1) Treat for shock. Follow the general principles of treating for hypovolemic shock (shock caused by diminished blood volume). Start an IV to replace lost body fluid.
- (2) Administer oxygen.

c. **Treatment for Hemothorax.** Follow the general principles of treating for hypovolemic shock (shock caused by a decrease in the amount of blood circulating in the body).

- (1) Survey the casualty and maintain the airway, if necessary.
- (2) Reassure the casualty.
- (3) Position the casualty. Place the casualty in the Fowler's position (elevate the casualty's head about 20 inches).
- (4) Administer oxygen. Establish an airway (clear the casualty's airway of obstructions and/or secretions and insert an oropharyngeal or endotracheal tube, if necessary). Then administer oxygen by mask or nasal catheter.
- (5) Initiate intravenous infusion (IV). Use serum albumin in the IV fluid because serum albumin draws fluid into the tissue. Run the IV flow wide open until the blood pressure returns to normal and stabilizes; then, decrease the flow to one drop per second. Start as many IVs as possible if shock is severe.
- (6) Maintain the casualty's normal body temperature. In cool temperatures, place the casualty on a poncho and cover him with the sides of the poncho. Use a wool blanket if you have one. DO NOT allow the casualty to lie in water. In hot or warm temperatures, DO NOT cover the casualty unless he shows signs of chilling. Watch the casualty for signs of sweating and/or chilling. Remove covering if the casualty is sweating. Cover the casualty if he shows signs of chilling.
- (7) Check vital signs. Check the casualty's vital signs and other symptoms as often as possible to see if he is responding to treatment. Check for consciousness, blood pressure, pulse rate, respirations, and skin color.
- (8) Evacuate the casualty. Record the treatment and evacuate the casualty to the nearest medical facility as soon as possible.
- (9) DO NOT drain the pleural space while you are in the field.

1-10. SIMPLE PNEUMOTHORAX

Simple pneumothorax is the presence of air within the pleural space. It results from blunt or penetrating trauma. Ninety percent of such injuries are associated with blunt trauma to the ribs. The fractured rib(s), in turn, cause injury to the pleura.

a. **Signs/Symptoms of Simple Pneumothorax.** Signs and symptoms include the following:

- (1) Pain that is sudden and sharp (in spontaneous pneumothorax).
- (2) Diminished or absent breath sounds.
- (3) Hyperresonance (exaggerated sound) on the affected side as detected by percussion.
- (4) Dyspnea (labored breathing) or gasping respiration.
- (5) Tracheal deviation toward the affected side.
- (6) A dry cough.

b. **Treatment of Simple Pneumothorax.** To treat simple pneumothorax, you should:

- (1) Maintain the airway.
- (2) Administer oxygen.
- (3) If the wound is small, the vital signs are stable, and there is no respiratory distress, transport the casualty in a position that is comfortable for him.
- (4) If the wound is large, perform chest decompression. Symptoms of a large wound are:
 - (a) Marked respiratory distress.
 - (b) Tachycardia (rapid pulse).
 - (c) Hypotension (low blood pressure).

1-11. SUBCUTANEOUS EMPHYSEMA

The presence of air or gas in the subcutaneous tissues is called subcutaneous emphysema. This condition can be caused by a blow to the chest which has caused a lung laceration from a fractured rib. If the chest injury is very severe, subcutaneous emphysema can involve the entire chest, neck, and face.

a. **Signs/Symptoms of Subcutaneous Emphysema.** The signs and symptoms include the following:

(1) Soft-tissue crepitus. As you feel over the area of the fracture with your fingertips, you will feel skin that seems like rice krispies.

(2) Occasionally, you will hear crackling sounds when you auscultate the chest.

b. **Treatment of Subcutaneous Emphysema.** To treat subcutaneous emphysema, you should:

(1) Determine the underlying injury--fractured rib, lung laceration, etc.--and treat the injury.

(2) Have the casualty rest.

(3) Monitor respiration.

(4) Administer oxygen. If you use the highest concentration possible, you may reduce the signs and symptoms.

1-12. OPEN PNEUMOTHORAX

Open pneumothorax, also called sucking chest wound, occurs as a result of an external penetrating trauma such as a shotgun wound at close range. The gunshot lacerates (tears) the flesh leaving an open wound. The open wound allows air to enter the chest cavity through the wound each time the casualty inhales and the chest expands in the normal respiratory cycle. In this situation, the air remains outside the lung in the pleural space. When the casualty exhales, air goes back outside through the wound. The lung, due to air in the pleural space, has not been able to fill and function properly.

a. **Signs/Symptoms of Open Pneumothorax.**

(1) Bloody froth in the wound when the casualty breathes out.

(2) A sucking sound at the wound site each time the casualty breathes in.

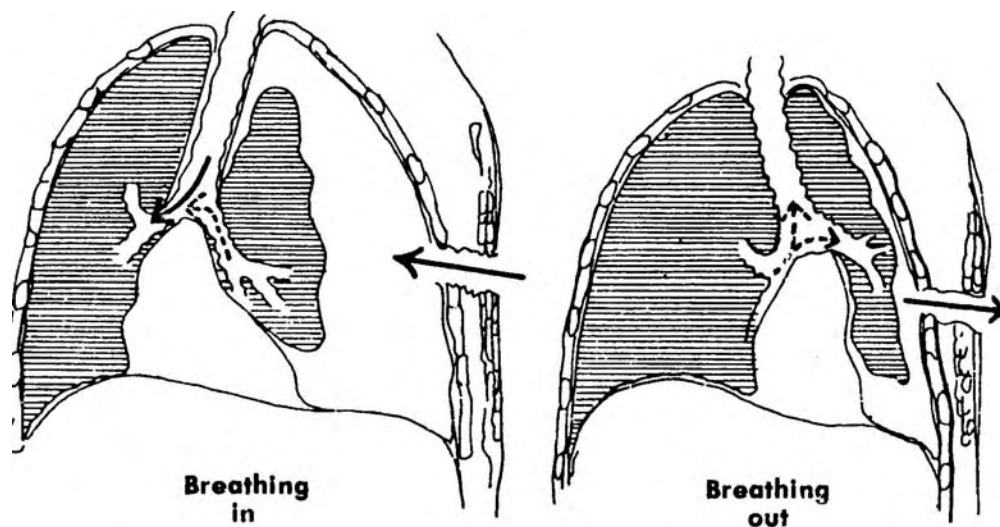


Figure 1-3. Open pneumothorax.

b. **Treatment for Open Pneumothorax.** To treat for open pneumothorax, you should:

(1) Seal the wound immediately with your hand or any available material. The goal is to seal the wound; therefore, use a nonporous material, if possible, such as aluminum foil, or a rolled up 8 x 10 dressing held in place. Be sure the dressing is large enough to cover the wound; otherwise, the dressing might be sucked into the wound.

(2) As soon as possible, apply a petroleum gauze dressing on the wound, and cover the dressing with a bulky dressing taped in place.

(3) Administer oxygen with positive pressure, as needed.

(4) Place the casualty in the semi-Fowler's position or any other position that is comfortable. If he is unconscious, lay him on his injured side.

(5) Observe the casualty for signs and symptoms of shock.

(6) Evacuate the casualty immediately.

(7) Give the casualty an IV with serum albumin.

1-13. TENSION PNEUMOTHORAX

Tension pneumothorax, a complication of hemothorax and pneumothorax, is a type of pneumothorax in which the intra-pleural pressure is greater than the atmospheric pressure. A leak in the lung has occurred, and that leak has failed to seal when the lung collapsed. With every breath the casualty takes, air continuously leaks out of the lung into the chest cavity. The lung collapses more with every breath until finally the lung is a small ball, perhaps two or three inches in diameter. If this condition is not corrected, it will be fatal.

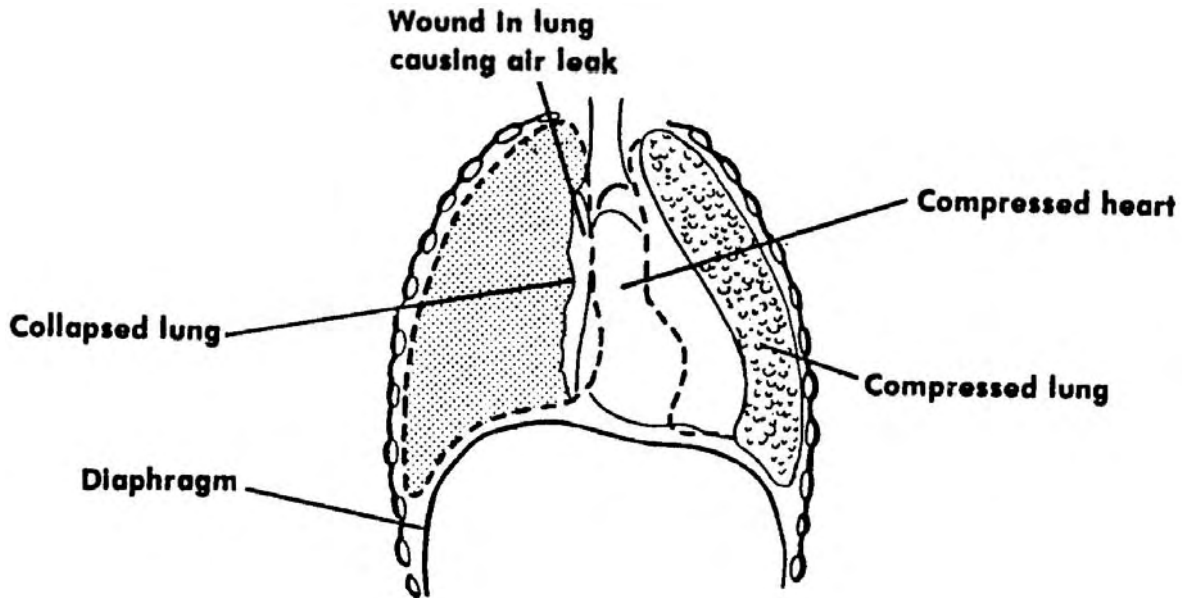


Figure 1-4. Tension pneumothorax.

a. Characteristics of Tension Pneumothorax.

(1) The margins or edges of the tear in the pleura are positioned to form a one-way valve. This valve permits air to enter the pleural sac during inspiration (breathing in) but prevents air from escaping during expiration (breathing out) so that each excursion (breath) tends to increase the pressure in the chest. This causes the other lung and the heart to be compressed.

(2) Additionally, the heart and mediastinum are pushed away from the injured side.

(3) Ventilation (air in lungs is exchanged with atmospheric air) and circulation are impaired.

b. Signs/Symptoms of Tension Pneumothorax.

- (1) Rib fracture or a penetrating wound.
- (2) Progressive respiratory distress.
- (3) Subcutaneous emphysema. Refer to paragraph 1-11. In this case, there is severe involvement of the entire chest, face, and neck. The area may appear grotesque and/or bloated.
- (4) Pain on the affected side.
- (5) The affected side will appear more prominent and move less. Air will remain trapped within the pleural cavity on exhalation.
- (6) Breath sounds will be distant or absent on the affected side.
- (7) Percussion reveals hyperresonance (exaggerated resonance on the affected side).
- (8) Progressive distention of the abdomen that is not relieved by gastric aspiration (removal of fluids from the stomach) and endotracheal intubation.
- (9) Deep cyanosis (bluish discoloration of the skin caused by insufficient oxygen in the blood).
- (10) Shock.

c. Treatment of Tension Pneumothorax.

- (1) Perform thoracentesis, if required. Thoracentesis is a method of removing air or fluids by suction (aspirating) by surgical puncture of the chest wall into the parietal cavity. To perform thoracentesis, follow this procedure:
 - (a) Gather equipment according to local standing operating procedure (SOP).
 - (b) Locate the proper site of entry by counting ribs. The site will be high if you are removing air and lower if you are removing fluid. For air, the site of entry is the midclavicular area of the second intercostal space. (The second intercostal space is the space between the second and third ribs). To remove fluid, the site is the intercostal space between the sixth and seventh ribs. To locate the specific ribs, count backward from the twelfth rib (see figure 1-5).
 - (c) Prep the skin with an antiseptic swab and drape with sterile towels.

(d) Follow local standing operating procedure (SOP) for the complete procedure.

(e) Aspirate air or fluid from the chest cavity. Continue aspiration until there is no more air or fluid to remove or until over 500 ml of blood or 1000 ml of air have been removed. A tube thoracostomy (a surgical creation of an opening into the chest wall) is usually performed when the casualty is evacuated to a treatment facility.

(2) Perform chest decompression.

(a) For closed injuries, insert a large bore needle into the second intercostal (ICS) mid-clavicular line (MCL). The plunger rises on its own when under pressure.

(b) For an open injury, cover the injury with a dressing and periodically remove the dressing to let air escape.

(3) Perform a tube thoracostomy using the second intercostal mid-clavicular line. This procedure is a must if the casualty is to be air-transported.

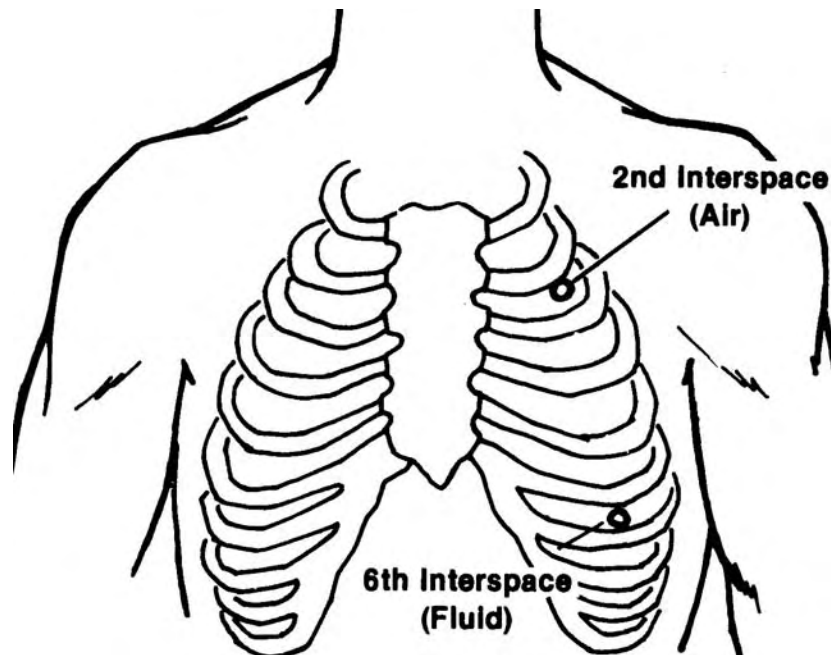


Figure 1-5. Needle insertion site for tension pneumothorax.

(4) Give the highest concentration of oxygen possible. Use positive pressure as needed. The positive pressure may increase tension; however, if decompression has been accomplished (air removed from the chest cavity), the lungs may expand.

- (5) Place the casualty in the Fowler's position, as tolerated.
- (6) Start an IV using normal saline or Ringer's solution.
- (7) Monitor the casualty's cardiac rhythm.

Section III. CHEST DECOMPRESSION

1-14. GENERAL INFORMATION

Chest decompression is the removal of air or blood from the chest cavity through a seal or valve device. Once the chest cavity is emptied of air or blood, the lung can expand and pressure in the chest cavity once again becomes negative.

a. **Indications of Need for Chest Decompression.** Any casualty with one of the following chest injuries will probably need chest decompression:

- (1) Tension pneumothorax (collapsed lung).
- (2) Hemothorax (accumulation of blood in the pleural cavity).
- (3) Simple pneumothorax (accumulation of air in the thorax), if the wound is large.
- (4) Flail chest with pneumothorax.

b. **Complications Associated with Chest Decompression.** Complications which may occur include the following:

- (1) Bleeding from the intercostal artery.
- (2) Lung puncture.
- (3) Hitting a pulmonary vessel.

1-15. NEEDLE CHEST DECOMPRESSION

a. **Symptoms.** Needle chest decompression is indicated if one of the following conditions exists: the casualty has tension pneumothorax; air must be released from the casualty's chest and adequate instruments are not available; the casualty has massive pneumothorax with mediastinal shift or without mediastinal shift.

b. **Procedures for Needle Chest Decompression.** To perform a needle chest decompression, complete the following steps taking care NOT to injure the casualty further.

(1) Gather equipment. You will need the following items:

- (a) Stethoscope.
- (b) Large bore needle (12 to 14 gauge).
- (c) 30 to 50 ml syringe.
- (d) Iodine swab.
- (e) DD Form 1380 (Field Medical Card).
- (f) Pencil.

(2) Verify the presence of pneumothorax. Do this by checking for indications of the condition.

CAUTION: Correct assessment is essential. If a needle is inserted into a normal chest, the casualty will almost certainly develop pneumothorax.

(a) Ask the casualty if there is a sharp pain on the affected side. Ask for any information related to the condition; for example, pain, trauma, or difficulty in breathing.

(b) Look for signs and symptoms of shock--decreased temperature; weak, thready pulse; rapid, shallow respirations; etc.

(c) Check for lack of chest excursion by observing the rising and falling of the chest during the casualty's respirations. Also, compare chest excursion on both sides of the chest to see if the chest rises and falls equally on both sides.

(d) Look for mediastinal (the mass of organs and tissues separating the two lungs) shift. Two signs of mediastinal shift are a tracheal deviation and/or distention of the jugular vein.

(e) Look for unilateral distention (change affecting one side) in this manner:

- 1 Place one hand on the affected area.
- 2 Place the other hand on the unaffected side.

3 Observe the height of each hand.

4 Determine if the height of the hand on the affected side is greater during expiration than the height of the hand on the unaffected side.

(f) Look and listen for the casualty gasping for air (dyspnea). Dyspnea may be present, but is not always an indication of pneumothorax.

(g) Look at and feel the casualty's chest for signs of subcutaneous emphysema.

(h) Tap the chest for tympany (a sound heard when percussing the chest). Percuss the chest in this manner:

1 Position the middle finger of one hand on the superior portion of the unaffected side.

2 Sharply tap the positioned finger with the middle finger of the other hand.

3 Repeat the previous two steps and listen for tympany on the affected side.

4 Repeat tapping the chest for tympany in successively lower positions on the chest until the entire chest has been percussed.

(i) Listen for diminished breath sounds.

1 Place the stethoscope on the unaffected side to establish normal breath sounds.

2 Listen to the affected side to determine if the breath sounds are fainter. The pneumothorax may be bilateral (affecting both sides of the chest).

(3) Locate the insertion site.

(a) Locate the sternomanubrial joint (Angle of Louis).

(b) Start at the sternomanubrial joint and follow the adjacent intercostal space to the mid-clavicular line.

- (4) Clean the insertion site.
 - (a) Remove the swab from the wrapper.
 - (b) Clean from the insertion site outward in a circular motion for 3 to 4 inches.
- (5) Insert the needle with the attached syringe.
 - (a) Place the needle tip, bevel up, on the insertion site, centered on the third rib.
 - (b) Lower the proximal end of the needle to permit the tip to enter the skin over the third rib.
 - (c) Insert the needle into the skin over the third rib until you have penetrated the pleura. When the pleura is penetrated, you will feel a "POP" followed by expulsion of air through the needle.
- (6) Aspirate air. Aspirate as much air as necessary to relieve the patient's acute symptoms.

CAUTION: Avoid puncturing blood vessels and nerves!

- (7) Withdraw the needle.
 - (a) Look for signs of respiratory relief as evidenced by the absence of the symptoms of pneumothorax.
 - (b) Withdraw the needle along the angle of insertion.
- (8) Record. If you are in a field setting, record the treatment on the Field Medical Card.

1-16. CATHETER-OVER-NEEDLE CHEST DECOMPRESSION

Perform a catheter-over-needle chest decompression. To do this procedure correctly, you must perform the following steps in sequence being careful not to cause further injury to the casualty.

- a. Gather your equipment. You will need the following items:
 - (1) Stethoscope.
 - (2) Catheter-over-needle device (12 to 14 gauge).

- (3) Iodine swab.
- (4) Adhesive tape, 6 inches of 1/2 inch wide tape.
- (5) DD Form 1380 (Field Medical Card.)
- (6) Pencil.

b. Verify the presence of pneumothorax by checking for indications of this chest injury. Follow the same verification procedures as for needle chest decompression listed in paragraphs 1-15a(2)(a) through 1-15a(3)(a)(i).

- c. Locate the insertion site. Follow procedure explained in 1-15a(3)(a) and (b).
- d. Clean the insertion site as in 15a(4)(a) and (b).
- e. Insert the needle.

(1) Place the needle tip, bevel up, on the insertion site, centered on the third rib.

(2) Lower the proximal end of the needle to permit the tip to enter the skin over the third rib.

(3) Insert the needle into the skin over the third rib, until the pleura has been penetrated, as evidenced by feeling a "POP", followed by expulsion of air through the needle.

(4) Hold the exposed end of the needle so it will NOT move.

f. Push the catheter into the pleural space until you feel resistance when the catheter meets the apex of the lungs.

g. While you keep the catheter from moving, withdraw the needle along the angle of insertion.

h. Secure the catheter to the chest.

i. If you are in a field situation, record the treatment on the Field Medical Card.

Continue with Exercises

EXERCISES, LESSON 1

INSTRUCTIONS. Answer the following exercises by writing the answer in the space provided.

After you have completed all of these exercises, turn to "Solutions to Exercises" at the end of the lesson and check your answers. For each exercise answered incorrectly, reread the material referenced with the solution.

1. List three common causes (listed in this lesson) of penetrating/nonpenetrating chest injuries.
 - a. _____.
 - b. _____.
 - c. _____.

2. List four common signs/symptoms of chest injuries.
 - a. _____.
 - b. _____.
 - c. _____.
 - d. _____.

3. When you examine a casualty to detect a chest injury, you should:
 - a. Question the casualty if he is. _____
 - b. Observe the casualty's bare chest and upper abdomen for _____ and depth.
 - c. Check for _____ on both sides of the chest.
 - d. Examine the _____ (including the back) beneath any overlying clothing.
 - e. Listen to the casualty's chest near the _____ and compare both sides of the chest for _____, _____, and equality

4. Rib and sternum damage, flail chest, and cardiac contusion are examples of _____ chest injuries.
5. A penetrating chest injury may be a hole in the thoracic cavity that allows _____.
6. Follow these general principles of treatment for chest trauma:
 - a. Keep the pleural space _____ by suctioning, if necessary.
 - b. Give oxygen to maintain proper level of oxygen in the body and to _____.
 - c. Estimate the amount of hemorrhage the casualty has, and _____.
 - d. Suction to keep the bronchial tree clear of retained blood, _____, and bronchial secretions.
7. _____ is a chest injury in which the pressure in the pleural cavity is greater than the atmospheric pressure.
8. A casualty with a chest injury is experiencing paradoxical respirations (the chest expands when he exhales and the chest contracts when he inhales). The name of the chest injury is probably _____.

9. List two indications for needle chest decompression.
- a. _____.
- b. _____.
10. The needle used for a needle chest decompression is a _____ needle.
11. Insertion of a needle into the pleural space of a casualty who does not have pneumothorax will result in the person having _____.
12. When tapping the chest for tympany, you should use the middle finger of one hand and _____ of the other hand.
13. When performing a needle chest decompression, insert the needle

Check Your Answers on Next Page

SOLUTIONS TO EXERCISES, LESSON 1

1. You are correct if you listed any three of the following:

Automobile accidents.
Falls.
Gunshot wounds.
Stab wounds.
Crushing injuries. (para 1-1)

2. You are correct if you listed any four of the following:

Normal breathing pattern change.
Pain at injury site.
Dyspnea (shortness of breath).
Chest doesn't expand.
Rapid/weak pulse.
Low blood pressure.
Dry or bloody cough.
Sucking sound on respiration.
Cyanosis.
Hemoptysis. (paras 1-2a through 1-2j)

3. a. conscious

b. Respiratory rate.

c. Equal movement.

d. Entire chest wall.

e. Armpits, volume, loudness. (paras 1-3a through 1-3e)

4. Blunt. (paras 1-6a, 1-7, 1-8)

5. Air enter the thorax thus filling that cavity with air. (para 1-4a)

6. a. Empty.

b. Remove carbon dioxide.

c. Replace the blood as necessary.

d. Foreign material. (paras 1-5a through 5e)

7. Tension pneumothorax. (para 1-13)
8. Flail chest. (para 1-7a)
9. You are correct if you listed any two of the following:
 - . Casualty has tension pneumothorax.
 - . Casualty needs emergency release of air from the pleural cavity and adequate instruments are not available.
 - . Casualty has massive pneumothorax with or without mediastinal shift. (para 1-15a)
10. 12 to 14 gauge large bore. (paras 1-15b(1)(b))
11. Pneumothorax. (para 1-15b(2) CAUTION)
12. The middle finger. (paras 1-15b(2)(h) 1, 2.)
13. Into the skin over the third rib. (para 1-15b(5)(c))

End of Lesson 1

LESSON ASSIGNMENT

LESSON 2

Airway Management.

LESSON ASSIGNMENT

Paragraphs 2-1 through 2-13.

LESSON OBJECTIVES

After completing this lesson, you should be able to:

- 2-1. State the purpose of using an esophageal obturator airway (EOA) or an esophageal gastric tube airway (EGTA).
- 2-2. Identify the advantages/ disadvantages of using an EOA or an EGTA.
- 2-3. Identify the indications/ contraindications of using an EOA or an EGTA.
- 2-4. Place the steps of intubating with an EOA or an EGTA in the correct order of performance.
- 2-5. Place the steps of extubating an EOA or an EGTA in the correct order of performance.
- 2-6. Identify the advantages/disadvantages of using an endotracheal tube (ET).
- 2-7. Identify the indications/contraindications of using an ET.
- 2-8. Place the steps for intubating with an ET in the correct order of performance.
- 2-9. Place the steps for extubating an ET in the correct order of performance.

SUGGESTION

After completing the assignment, complete the exercises of this lesson. These exercises will help you to achieve the lesson objectives.

Section I. ESOPHAGEAL OBTURATOR AIRWAY

2-1. INTRODUCTION

Intubation, a valuable technique, is used frequently in the administration of anesthesia, cardiopulmonary resuscitation, and respiratory therapy. The procedure improves safety by establishing and maintaining the casualty's airway, allowing the surgeon greater freedom of access to the operative field, and improving aseptic technique for head and neck surgery. However, the procedure requires both a knowledgeable and skillful medical specialist. The esophageal obturator airway (EOA) is a long tube open at the top, sealed at the bottom, with numerous side holes near its upper end. The esophageal gastric tube airway (EGTA) is a variation of the EOA. It has no holes on the tube, but the tip of the obturator is open rather than closed. The technique for passing (inserting) the EOA and the EGTA are the same. Neither the EOA nor the EGTA provides the perfect answer to controlling the airway and neither should be considered as replacements for endotracheal intubation (ET). Their most appropriate use is as an interim form of airway control in patients who are difficult to intubate endotracheally.

2-2. PURPOSE OF THE EOA AND EGTA

The esophageal obturator airway and the esophageal gastric tube airway have several important purposes. Each device, when inserted, holds the tongue away from the pharynx allowing ventilated air to move through the trachea into the lungs. Additionally, the EOA and the EGTA, when inserted, seal off the stomach from the airway thus preventing gastric acid from coming back into the pharynx. The EGTA can be used for gastric lavage (washing out the stomach) and gavage (forced feeding by flexible tube and pump).

2-3. ADVANTAGES/DISADVANTAGES OF THE EOA AND EGTA

a. **Advantages of EOA and EGTA.** There are two main advantages in using these devices. First, both the EOA and the EGTA are easy to place. Second, only minimal training is required to learn to place the devices properly.

b. **Disadvantages of EOA and EGTA.** These are the disadvantages. These devices DO NOT allow a direct pathway into the larynx for suctioning. The mask face seal must be good for ventilation. It is possible to cause pharyngeal trauma to the patient during insertion of the device. It is possible to accidentally enter the trachea and totally obstruct the airway. Finally, if the cuff of the EOA is not properly inflated, gastric distention and impaired ventilation can be caused. Neither of these devices should be used on anyone less than five feet tall; the tubes are too long for people of such height.

2-4. INDICATIONS/CONTRAINDICATIONS OF THE EOA AND EGTA

a. **Indications for Use of the EOA and EGTA.** Either of these devices can be used if one of the following conditions exist: the casualty is in a deep coma; the casualty has shallow respirations; the casualty has progressive cyanosis; the casualty has cardiopulmonary arrest.

NOTE: The EGTA may be used for gastric lavage (washing out of the stomach) or gavage (forced feeding by flexible tube and pump) which might be required for a patient who has taken an overdose of drugs.

b. **Contraindications for Use of EOA and EGTA.** These devices should not be used if these conditions exist. Do not use if the casualty is conscious and/or is breathing effectively on his own. The gag reflex may operate causing the casualty to retch or choke. Do not use either device on infants, children, or adults under five feet tall. Devices small enough to fit these individuals have not been developed. Do not use EOAs or EGTA's if the casualty has facial damage, esophageal disease, or if the casualty has ingested a caustic substance.

2-5. INTUBATING WITH AN EOA AND EGTA

a. **Equipment.** The following equipment will be needed to perform an EOA or EGTA intubation:

- (1) Esophageal obturator airway (EOA or EGTA)
- (2) 50 cc syringe.
- (3) Lubricating jelly (K-Y or Lidocaine Jelly).
- (4) EGTA (gastric tube).
- (5) EOA (suction device).

b. **Procedural Steps for Intubating.** Complete the following steps:

- (1) Gather the equipment:
 - (a) EOA or EGTA syringe.
 - (b) K-Y lubricant.

(c) Bag-valve-mask (BVM) or oxygen with demand valve. Check the BVM each time prior to use, particularly the cuff. Also, check the corneal reflex and the gag reflex. Check the casualty for the presence of a corneal reflex by touching the casualty's cornea with your fingers. If the eyelid does not try to close, continue with the procedure. If the eyelid tries to close (blink), the gag reflex is still present and you cannot proceed with insertion of the device. Periodically recheck for the reflex, and when the eyelid does not try to close, continue with the procedure.

(2) Lubricate the EOA or EGTA.

(3) Oxygenate the casualty with two full, slow breaths.

(4) Grasp the casualty's tongue and jaw, lifting both upward and forward without hyperextending the neck.

(5) Grasp the tube below the mask using the fingers of your other hand.

(6) Insert the EOA or EGTA (without pushing hard) following the curve of the pharynx until the mask settles on the casualty's face.

(7) Seal the mask and check its placement by blowing into the tube and watching for the rise of the casualty's chest. (If the chest does not expand or rise, remove the tube quickly and reoxygenate.)

NOTE: You must wait 3 minutes before doing these procedures again.

(8) Inflate the balloon of the EOA or EGTA with no more than 35 ml of air.




Figure 2-1. Grasp the casualty's tongue and jaw.

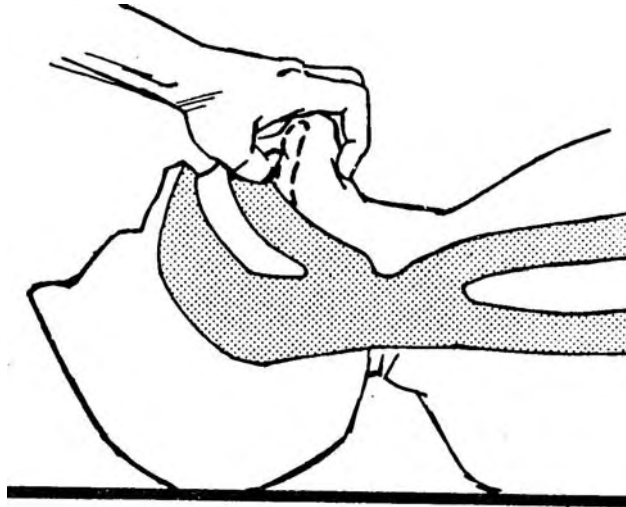


Figure 2-2. Lift the tongue and jaw upward.

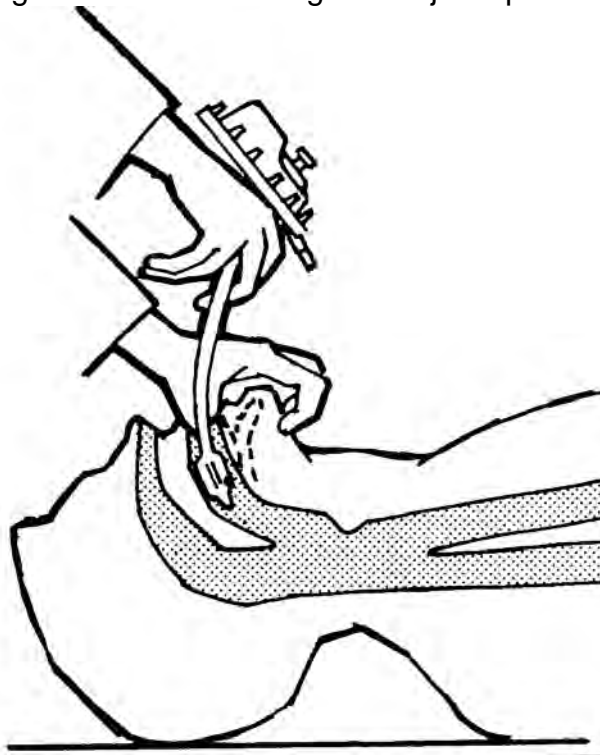


Figure 2-3. Insert the EOA or EGTA tip into the mouth.

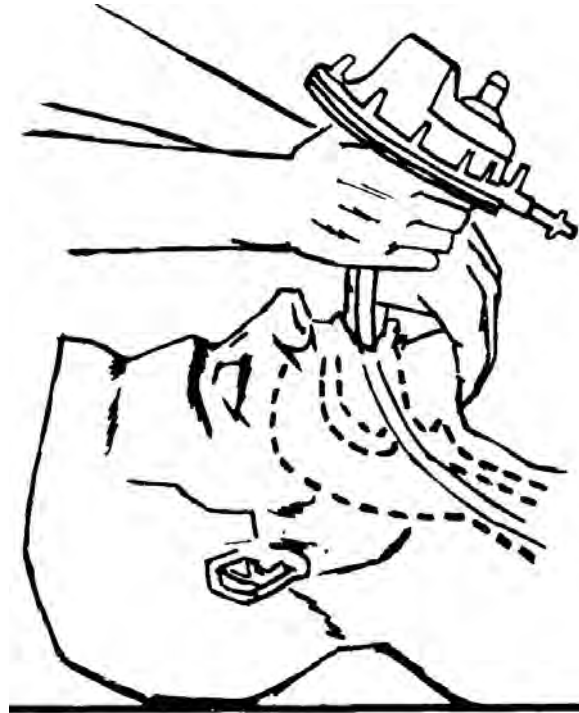


Figure 2-4. Continue inserting the EOA or EGTA following the curve of the pharynx.

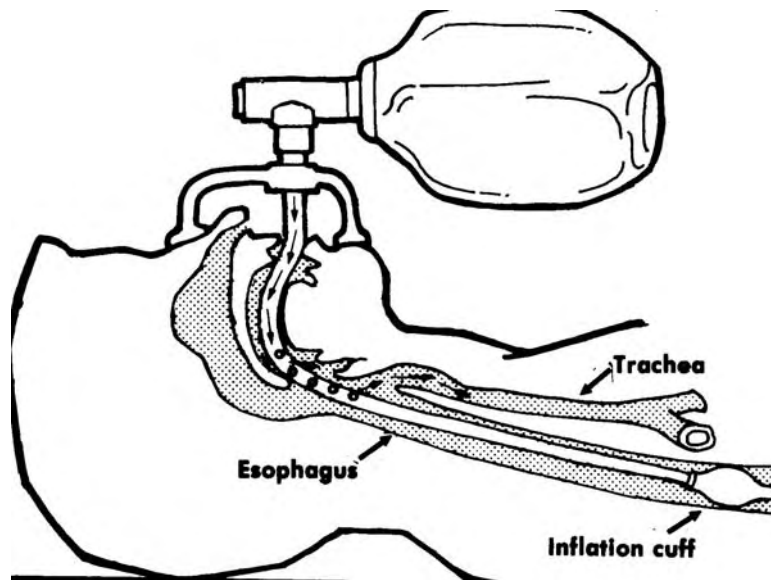


Figure 2-5. Inflate the balloon of the EOA or EGTA.

(9) Remove the syringe to allow self-sealing or clamp the cuff tube, if necessary.

(10) Auscultate to check placement of the EOA or EGTA by listening with a stethoscope to the two lower lung fields and the paraumbilical area. You should not hear a sound like rushing water.

(11) Ventilate once every 5 seconds using a bag-valve-mask (BMV) or a demand valve and oxygen.

NOTE: At any point during the procedure, the casualty should NOT be without oxygen for more than 30 seconds

2-6. EXTUBATING WITH AN EOA AND EGTA

CAUTION: The EOA or EGTA is not normally removed until the casualty is in the hospital unless the casualty begins to breathe on his own.

Follow these steps to extubate (remove) an EOA or an EGTA:

a. Oxygenate the casualty with two slow breaths. You can do this by blowing two slow breaths into the tube, or you can attach an ambu bag and squeeze it two times. What you are doing is giving the casualty a little too much oxygen to compensate for the time when he will not be getting quite enough oxygen--the time you are removing the EOA or the EGTA.

b. Pop off the face mask.

c. Turn the patient to one side.

d. Deflate the balloon cuff with the syringe.

e. Remove the tube following the curve of the pharynx.

f. Clear the airway of vomitus immediately.

Section II. ENDOTRACHEAL TUBE

2-7. INTRODUCTION

An endotracheal tube (ET) is a tube inserted into the trachea for administration of anesthesia, maintenance of an airway, aspirations of secretions, ventilation of the lungs, or prevention of the entrance of foreign material into the tracheobronchial tree. The two types of ETs dealt with in this lesson are the orotracheal tube and the nasotracheal tube. The orotracheal tube is inserted through the mouth into the trachea. The nasotracheal tube is inserted through the nose into the trachea. In this lesson, both the orotracheal tube and the nasotracheal tube are used to establish an airway.

2-8. ADVANTAGES/DISADVANTAGES OF ET

a. **Advantages of ET.** The chief advantage is that the endotracheal tube provides an unobstructed airway if the tube is properly placed. Air is channeled through the larynx and trachea to the lungs where it is needed. In normal breathing, some air breathed remains in the larynx and trachea where the air is unused. The space holding the unused air is called anatomic dead space, and the endotracheal tube reduces that space by about 50 percent. Once inserted, the ET prevents the casualty from breathing in secretions such as blood, stomach contents and bowel contents. The ET also makes positive pressure breathing (assisted or controlled) easier without gastric inflation.

b. **Disadvantages of ET.** With the ET in place, air goes directly through the mouth without being warmed, humidified, or filtered--all of which normally take place in the nasal passages. It is possible to cause further injury to the casualty by accidentally inserting the tube into the wrong area. A tube inserted into the esophagus, for example, can cause the airway to be completely obstructed. Also, the presence of the tube may be such an irritant to the casualty's body that he may have breathing problems. The tube may cause bronchial spasms or increase the production of mucous, both make it more difficult for air to reach the casualty's lungs.

2-9. INDICATIONS/CONTRAINDICATIONS FOR USE OF ET

a. **Indications.** Indications for using the endotracheal tube are the same as for using the esophageal obturator airway--casualty in deep coma, casualty with shallow respirations, casualty has progressive cyanosis, or casualty has cardiopulmonary arrest. Additionally, use the ET when preparing a person before surgery for anesthesia. The ET is used in all types of surgery where the casualty's position makes it impossible to use a mask; for example, the prone (lying face downward), lateral (lying on side with top knee bent for balance), or sitting positions. The ET is used if a tight mask fit is not possible due to "atypical" (abnormal) facial contours caused by disease, obesity, etc.

b. **Contraindications.** Don't use the endotracheal tube if there is upper airway obstruction due to foreign bodies. Use the endotracheal tube with caution if there is swelling in the larynx or if the patient has mandibular (horseshoe-shaped bone forming the lower jaw) or cervical (neck) fractures. Attempts at intubation may make these injuries worse.

2-10. INTUBATING WITH AN ET

a. **Equipment.** Endotracheal tubes are nontoxic, nonallergenic, and flexible. These tubes are able to maintain a curved shape and do not conduct electricity. There are two types of tubes: rubber tubes and plastic tubes. Rubber tubes include the Murphy, a blunt level type of endotracheal tube with an inflatable cuff. The Cole, a pediatric tube, is also made of rubber. Plastic tubes, can be either opaque or transparent; the Protex is an example of such a tube. The Protex tube is made of transparent vinyl plastic; the tube tends to bend although it is somewhat rigid.

(1) Tube size.

(a) Measure the external diameter of the tube in millimeters.

(b) The internal diameter is measured in millimeters. The internal diameter size is basically standard but may vary to about 0.5mm.

(c) To determine the length of the oral tube, measure the distance from the corner of the casualty's mouth to midsternum (mid breast bone).

(d) The casualty's nare size will determine the nasal tube's diameter. To determine the length of the nasal tube, measure the distance from the earlobe to the corner of the mouth and add the distance from the corner of the mouth to the midsternum. The radius of the curvature is greater for oral tubes. The bevel for the nasal tube has a sharper angle than for the oral tubes. There is also a difference in the inflatable cuffs.

(2) Inflatable cuffs. These are used to attain an airtight seal to prevent aspiration. The cuffs should be inflated so the balloon indents with thumb pressure. Such indentation usually occurs when the balloon has been inflated with five to ten milliliters of air.

(3) Stylet. The stylet allows the proper tube curvature to be maintained.

(4) Magill forceps. These are used to guide the nasal endotracheal tube into the larynx from the pharynx.

(5) Laryngoscope. This device is used to see the larynx. A laryngoscope has two different types of blades: the Miller blade which is straight and the MacIntosh blade which is curved. The component parts are:

(a) Handle ("L" type or right angle is the most commonly used handle). Handles come in small, medium, and large sizes.

(b) Flashlight and penlight batteries.

(c) A blade that snaps onto the handle.

b. Complications.

(1) In the process of inserting the tube, teeth may be broken or chipped; nasal, oral, and pharyngeal soft tissue may be damaged; or the vocal cord may be damaged.

(2) The tube may be accidentally pushed into the esophagus causing a total airway obstruction and finally death, if the situation is not corrected.

(3) If the tube is pushed into the bronchus (either of the two main branches of the trachea), the casualty may suffer pneumothorax, bronchospasm, laryngospasm, hypoxemia, cardiac arrhythmias, or irritation of the carina with subsequent coughing.

(4) Endotracheal tube obstruction. Foreign bodies, mucous, etc. may block the tube.

(5) The trachea or vocal cords may become ulcerated because of increased pressure by the ET cuff.

(6) After the endotracheal tube is removed, the casualty may experience laryngospasm (spasmodic closure of the larynx), infection, and hoarseness (sore throat).

2-11. PROCEDURAL STEPS FOR INTUBATING--OROTRACHEAL TUBE

Complete the following steps to intubate correctly:

a. Gather the equipment and check it.

(1) Tube. Select the type (vinyl, rubber, or plastic) and the size of the tube. Use anatomy considerations and measurements in your selection. (The inflatable cuff comes with the tube.)

(2) Stylet.

(3) Magill forceps. These forceps can be used to advance the tube between the vocal cords.

(4) Laryngoscope. Check this instrument for batteries and check the light. Select the blade you are going to use and assemble the blade. (The curved blade provides more working space, but the straight blade allows you to see better.)

(5) Suction apparatus with a tonsillar tip.

(6) J-tube (oropharyngeal) airway. A J-tube is a white plastic or black rubber tube that is used to keep the tongue out of the way.

(7) Anesthetic spray, if available.

b. Place the equipment next to the casualty's head, where the equipment is needed.

c. Position the casualty so that you have the best possible view of the larynx. The casualty should be in a "sniffing" position with a towel under his neck.

d. Turn on the suction apparatus.

NOTE: OPTIONAL PROCEDURE--place a stylet into the tube prior to oxygenation and insertion of the laryngoscope.

e. Check the casualty's corneal reflex and his gag reflex, then oxygenate the casualty with two slow breaths. Check the casualty for the presence of a corneal reflex by touching the casualty's cornea with your fingers. If the eyelid does not try to close, continue with the procedure. If the eyelid tries to close (blink), the gag reflex is still present, and you cannot proceed with insertion of the device. Periodically recheck for the reflex, and when the eyelid does not try to close, continue with the procedure.

f. Insert the laryngoscope and place the tube.

(1) Grasp the laryngoscope with your left hand.

(2) Insert the laryngoscope into the right side of the casualty's mouth.

(3) Bring the blade to the center or midline of the mouth, moving the tongue to the left side.

(4) Advance the blade a short distance.

(5) Visualize the epiglottis.

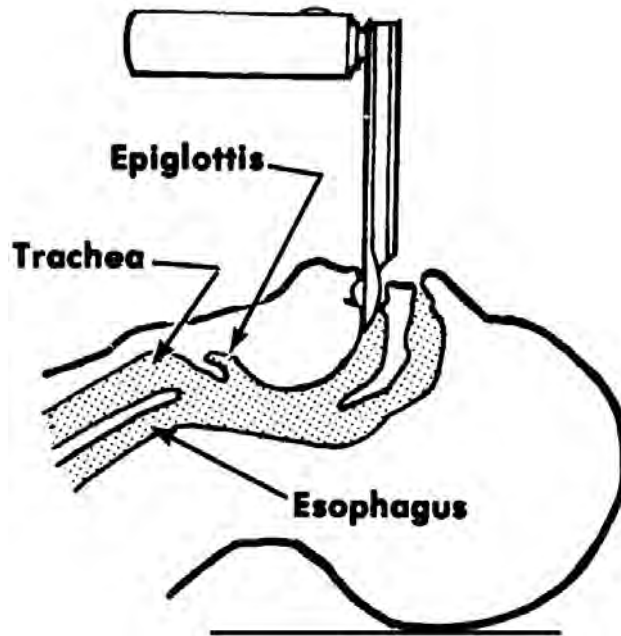


Figure 2-6. Placement of the laryngoscope.

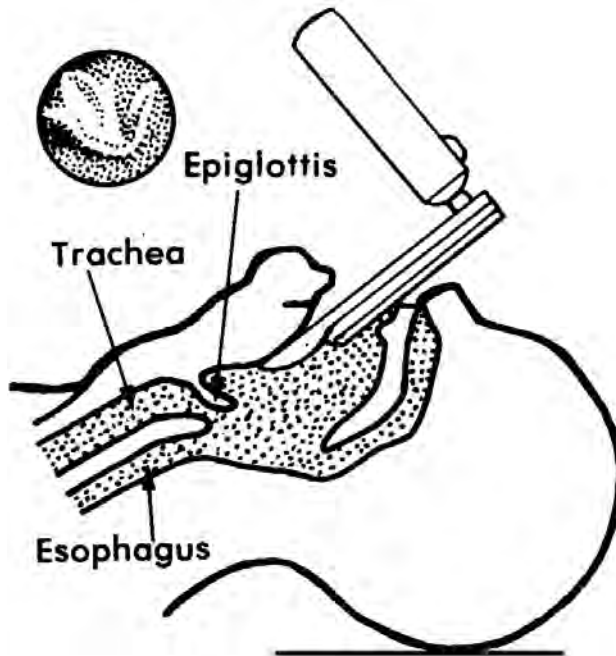


Figure 2-7. Visualization of the epiglottis.

(6) Advance the tip of the blade and lift it to visualize the vocal cords. If you are using a straight blade, place the tip of the blade under the epiglottis. If you are using a curved blade, put the tip of the blade on the vallecula (depression between the epiglottis and the root of the tongue, either side of the median glossoepiglottic fold).

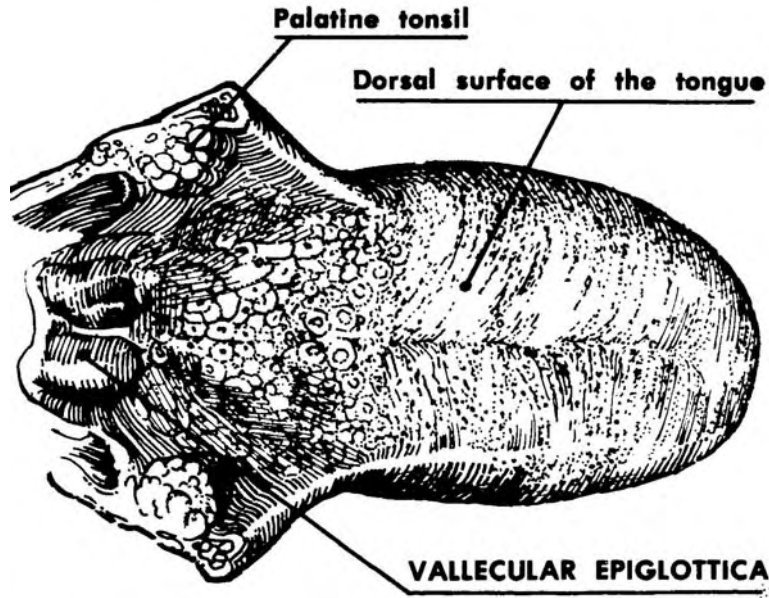


Figure 2-8. Vallecula epiglottica.

- (7) Grasp the tube with the right hand.
- (8) Advance the tip of the endotracheal tube carefully between the vocal cords until the upper cuff is below the level of the vocal cords.
- (9) Insert the oropharyngeal airway (J-tube) to act as a bite block.

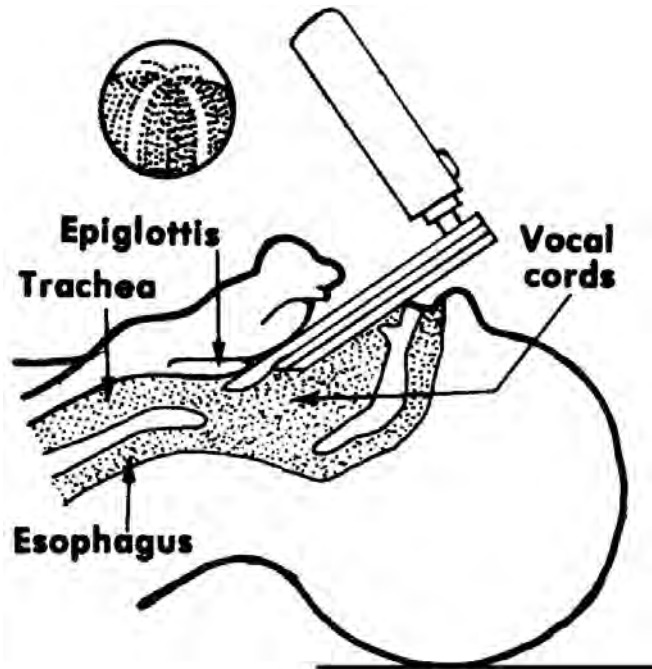


Figure 2-9. Visualization of the vocal cords.

g. Check the placement of the endotracheal tube. To check the placement:

(1) Breathe through the tube while someone auscultates the two lower lung fields and the paraumbilical (area alongside the navel) regions to check tube placement.

(2) If sound is heard over one lung field (usually the right) more than the other, you must back up the tube a little and listen again?

NOTE: If a rushing sound is heard over the abdomen with diffuse sound over the lower lung fields, you have missed the larynx and gone down into the pharynx. You should remove the tube, reoxygenate the casualty, wait three minutes, and try again.

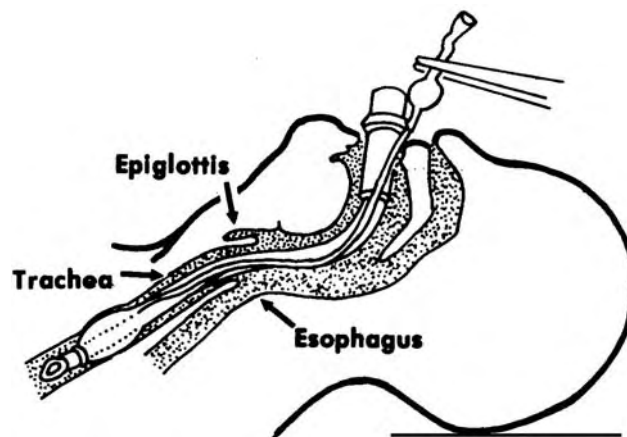


Figure 2-10. Properly placed endotracheal tube.

h. Inflate the cuff with 5 to 10 ml of air.

i. Reoxygenate the patient with two slow breaths.

j. Clamp the tube (optional) and remove the syringe.

k. Connect the resuscitative equipment (BVM or O₂ with demand valve).

l. Ventilate once every 5 seconds.

m. Secure the tube.

n. Monitor the casualty periodically with auscultation to be sure the endotracheal tube is placed correctly.

CAUTION: Be sure the casualty is NOT without oxygen for longer than 30 seconds at a time.

2-12. PROCEDURAL STEPS FOR INTUBATING--NASOTRACHEAL TUBE

- a. Intubate with a nasotracheal tube in the same way as you would with an orotracheal tube. There are some differences, and these differences are listed here.
- b. Use the most patent nare. That is, insert the tube in the nostril which is the most open.
- c. Advance the tube while you listen to breath sounds.
- d. Use the Magill forceps to advance the tube into the larynx. Begin using the forceps when the tube appears in the oropharynx.
- e. Be sure the bevel of the tube is adjacent to the nasal septum when the tube is being advanced.
- f. Tape the tube across the casualty's nose and cheek on the side that is used.

2-13. EXTUBATING AN ET

The procedure is the same for the nasotracheal tube and the orotracheal tube. Follow these steps:

- a. Suction the bronchial tree as required:
 - (1) Initiate cardiac monitoring.
 - (2) Preoxygenate for at least 3 minutes.
 - (3) Advance the catheter as far as possible with the suction off.
 - (4) Apply intermittent suction while slowly withdrawing the catheter in a rotating fashion.
 - (5) DO NOT apply suction for more than 5 seconds.
- b. Reoxygenate the patient with two slow breaths.
- c. Deflate the cuff using the syringe.
- d. Remove the tube at the end of inspiration (inhaling).
- e. Clear and maintain an open (patent) airway.

Continue with Exercises

EXERCISES, LESSON 2

INSTRUCTIONS. Answer the following exercises by writing the answer in the space provided.

After you have completed all of these exercises, turn to "Solutions to Exercises" at the end of the lesson and check your answers. For each exercise answered incorrectly, reread the material referenced with the solution.

1. List three purposes of the esophageal obturator airway (EOA) and the esophageal gastric tube airway (EGTA).
 - a. _____.
 - b. _____.
 - c. _____.

2. List the two main advantages of using the EOA or the EGTA.
 - a. _____.
 - b. _____.

3. List three conditions in which you would not use an EOA or EGTA.
 - a. _____.
 - b. _____.
 - c. _____.

4. Just before grasping the casualty's tongue and jaw (in the process of intubating with an EOA or EGTA, you should oxygenate the casualty with _____ full breaths.

5. During the time you are intubating with an EOA or EGTA, be sure the casualty is not without oxygen more than _____.

6. One possible complication of using an endotracheal tube is that the casualty may develop _____ of the trachea or vocal cords.
7. When you are inserting the EOA or EGTA, insert the tube following the curve of the pharynx until _____.
8. To seal the mask of an EOA or EGTA and check that the tube is properly placed, blow into the tube and watch for _____.
9. The chief advantage of the endotracheal tube, if properly placed, is that it provides _____.
10. If an endotracheal tube is in the casualty, air goes directly through the mouth and is not warmed, _____, or _____ functions normally performed by the nasal passages.
11. When you are using an endotracheal tube, determine the length of the tube by measuring the distance from the casualty's _____ and adding the distance from _____.
12. It is possible to cause damage when inserting an endotracheal tube; for example, teeth may be _____ or _____.
13. You are intubating with an orotracheal ET and hear a rushing sound over the abdomen along with sounds over the lower lung fields. You have missed the _____ and gone into the _____.

14. When intubating with an orotracheal ET, be sure the casualty does not go without oxygen for more than _____ at a time.
15. When intubating with a nasotracheal ET, be sure the _____ of the tube is adjacent to the nasal septum when the tube is being advanced.

Check Your Answers on Next Page

SOLUTIONS TO EXERCISES, LESSON 2

1. You are correct if you listed any three of the following:

Each device holds the tongue away from the pharynx, allowing ventilated air to move into the trachea.

Each device seals off the stomach from the airway, preventing gastric acid from coming back into the pharynx.

Each device can be used for gastric lavage (irrigation of the stomach).

Each device can be used for gavage (feeding through a tube passed into the stomach). (para 2-2)

2. The devices are easy to place.
Only a minimal amount of training is needed to use the devices. (para 2-3a)

3. You are correct if you listed any three of the following:

The casualty is conscious and breathing effectively on his own.

The casualty is an infant.

The casualty is an adult under 5 feet tall.

The casualty has facial damage.

The casualty has esophageal disease.

The casualty has ingested a caustic substance. (para 2-4b)

4. two. (para 2-5b(3))
5. 30 seconds. (para 2-5b(11))
6. Ulceration. (para 2-10b)
7. The mask settles on the casualty's face. (para 2-5b(6))
8. The rise of the casualty's chest. (para 2-5b(7))
9. An unobstructed airway. (para 2-8a)
10. Humidified, or filtered. (para 2-8b)
11. Earlobe to the corner of the mouth.
Corner of the casualty's mouth to the midsternum. (para 2-10a(1)(d))
12. Chipped or broken. (para 2-10b(1))
13. Larynx.
Pharynx. (para 2-11g(2) NOTE)

14. 30 seconds. (para 2-11n CAUTION)
15. Bevel. (para 2-12e)

End of Lesson 2

LESSON ASSIGNMENT

LESSON 3

Cricothyroidotomy

LESSON ASSIGNMENT

Paragraphs 3-1 through 3-9.

LESSON OBJECTIVES

After completing this lesson, you should be able to:

- 3-1. Define cricothyroidotomy.
- 3-2. Identify conditions requiring a cricothyroidotomy, types of cricothyroidotomy, and complications of cricothyroidotomy.
- 3-3. Identify signs/symptoms of an obstructed airway.
- 3-4. Place the steps of performing a needle and surgical cricothyroidotomy in the correct order of performance.

SUGGESTION

After completing the assignment, complete the exercises of this lesson. These exercises will help you to achieve the lesson objectives.

LESSON 3

CRICOTHYROIDOTOMY

Section I. GENERAL CONSIDERATIONS

3-1. DEFINITION

A cricothyroidotomy is an emergency surgical procedure to provide a temporary airway between the cricoid cartilage and thyroid cartilage because there is a total obstruction in the normal oropharyngeal air-exchange route. The cricothyroidotomy site consists of the larynx, which contains the thyroid cartilage (Adam's apple); the cricoid cartilage; the cricothyroid membrane (between the cartilages); the thyroid gland; and the vocal cords. In a needle cricothyroidotomy or a surgical cricothyroidotomy, the cricothyroid membrane is penetrated. Figure 3-1 shows the location of the cricothyroid membrane.

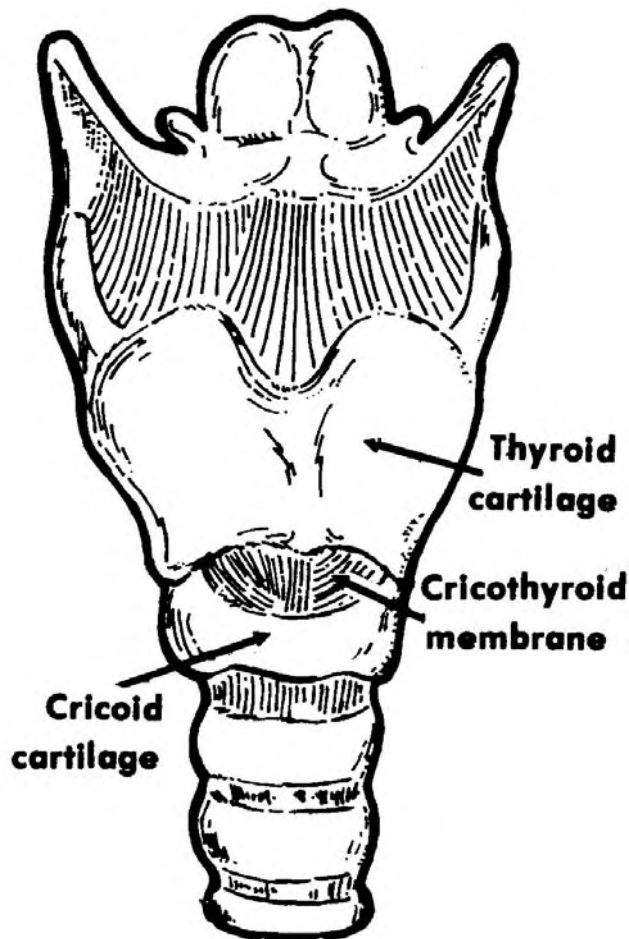


Figure 3-1. Location of the cricothyroid membrane.

3-2. CONDITIONS REQUIRING CRICOTHYROIDOTOMY

a. **Trauma to the Larynx.** A blow to the larynx with a blunt instrument can cause destruction of the structure that supports the larynx. This allows the airway to collapse during inspiration (breathing in) and to close. A blow to the larynx with a blunt object may cause severe swelling (edema). This swelling may not occur for up to 48 hours following the injury, and the swelling may result in the airway being closed. Monitor a casualty with possible or suspected injury to the larynx constantly during the period immediately following such an injury.

b. **Foreign Bodies/Objects.** Foreign bodies such as dislocated teeth or dentures or accumulations of blood, mucus, or vomitus. Foreign objects, accidentally ingested and obstructing the airway, may be the greatest cause of upper airway obstruction. In very young children, foreign objects in the airway may be the result of not knowing how to chew and swallow properly or an underdeveloped epiglottal reflex. In adults airway obstruction is frequently associated with eating coarse meats and vegetables. Airway obstruction in adults is often misdiagnosed as a heart attack (cafe coronary), but the person is really suffering from something obstructing the airway.

c. **Soft Tissue Involvement.** Soft tissue involvement may cause swelling which results in the airway being obstructed. Possible reasons for the swelling include an anaphylactic reaction or flash burns involving trauma to the larynx.

3-3. TYPES/COMPLICATIONS

a. **Types.** There are two types of cricothyroidotomy: needle cricothyroidotomy (also called percutaneous transtracheal ventilation) and surgical cricothyroidotomy.

b. **Complications.** Although a cricothyroidotomy is a relatively safe procedure, complications can occur. Bleeding is the most common complication, but it is usually minor and controllable. False passage is another complication: that is, accidentally entering a passage other than the airway. Complications also include damage to the vocal cords and larynx (if the incision is made incorrectly), mediastinal emphysema, subcutaneous emphysems, and infection.

CAUTION: Resuscitation techniques may be necessary. In such a case, use a bag-valve--mask, demand valve resuscitator, and suction device.

3-4. SIGNS/SYMPTOMS OF AN OBSTRUCTED AIRWAY

The absence of respiration, universal choking sign, and inability to speak are all signs/symptoms of an obstructed airway. On looking at the casualty, you may see that his chest is fully expanded with the rib margins being prominent while the intercostal spaces are depressed. Another sign is slightly bluish discoloration of the skin and mucous membrane because of oxygen deficiency (cyanosis).

Section II. NEEDLE CRICOTHYROIDOTOMY

3-5. EQUIPMENT

To perform a needle cricothyroidotomy, you will need this equipment: iodine preparation kit, large bore needles (12-gauge or 14-gauge), cannula-over-needle device (optional), and tape.

3-6. PROCEDURE

This procedure must be done within four minutes.

- a. Place the casualty in the supine position.
- b. Extend the casualty's neck by placing a large, rolled-up towel or pillow under his neck or between his shoulder blades so that the airway is straight. Prep the area with povidine-iodine.
- c. If you suspect that the casualty has a cervical (neck) injury, DO NOT extend the neck.
- d. Palpate the thyroid notch and the cricoid cartilage and locate the cricothyroid membrane.
- e. Stabilize the larynx between the thumb and the index and middle fingers of one hand and firmly insert the needle perpendicularly into the membrane.

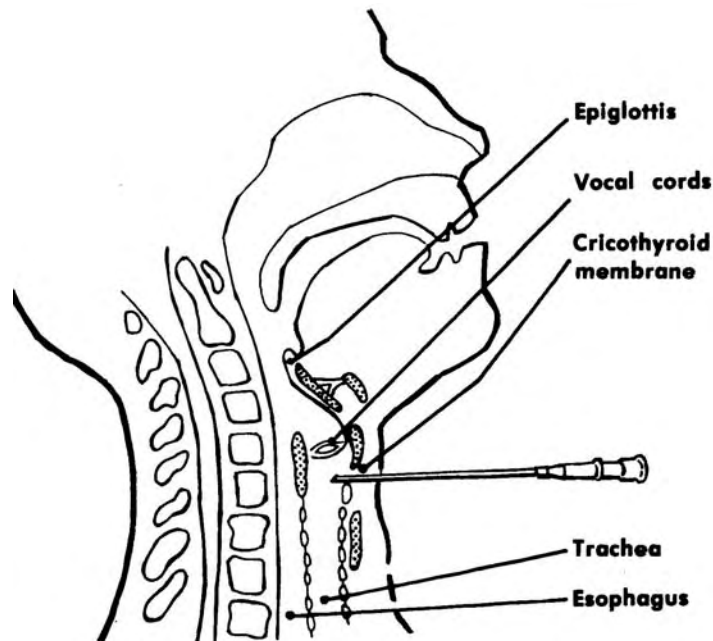


Figure 3-2. Inserting the needle perpendicularly into the cricothyroid membrane.

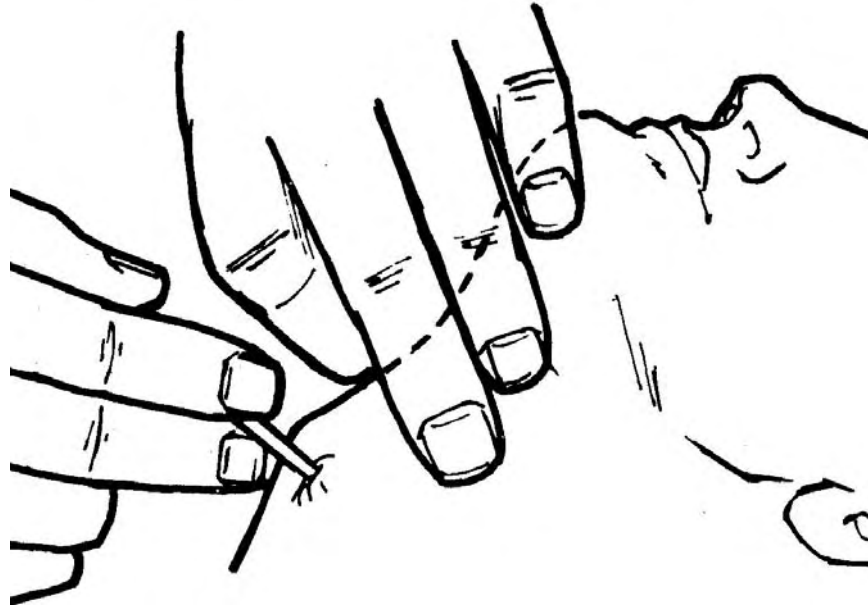


Figure 3-3. Inserting the needle.

f. As the larynx is entered, air will pass back and forth through the needle with the patient's respiratory activity.

g. When the needle is inside the larynx, direct it downward and toward the back (posteriorly) to avoid penetrating the esophagus. Insert an additional needle if the airway you have formed is not sufficient.

CAUTION: This procedure is more risky on a casualty with a tendency to bleed readily or with a large, thick neck. It may be difficult to locate the cricothyroid membrane on a person with a thick neck. If you feel resistance when the needle passes through the cricothyroid membrane, the needle has penetrated the other side of the tracheal cartilage.

h. Stabilize the needle with adhesive tape. Wrap a 6-inch to 8-inch strip of tape around the needles once at the place where the needles exit the skin. Press the ends of the tape around the needles so the needles are held in place and do not come off.

i. Keep the casualty's head relatively immobile.

j. Make preparations for a more permanent airway control. Use an endotracheal intubation or tracheostomy if the airway needs to be artificially maintained for a prolonged time.

k. The procedure may be varied by using a cannula-over-needle device. To do this, remove the needle and allow the catheter to remain in place after it is positioned.

Section III. SURGICAL CRICOTHYROIDOTOMY

3-7. GENERAL

A surgical cricothyroidotomy is the first treatment action when the airway is obstructed by swelling associated with burns, anaphylactic reaction, edema, or a crushing injury to the larynx. IT IS THE LAST RESORT FOR ALL OTHER TYPES OF OBSTRUCTION. This task should NOT be performed on infants and children. Only casualties with a total upper airway obstruction or casualties with inhalation burns should be considered for surgical cricothyroidotomy.

3-8. EQUIPMENT

To perform surgical cricothyroidotomy, you will need the following equipment:

a. Any cutting instrument:

- (1) Scissors.
- (2) Pocket knife.
- (3) Tin can (edge).
- (4) Scalpel.

b. If a dilator (an instrument used for stretching an opening) is not available, you may use one of the following to enlarge the opening:

- (1) Hemostats (small surgical clamp for constricting a blood vessel).
- (2) Needle holders.
- (3) Small retractors (Weitlaner).
- (4) Knife handle.
- (5) Pair of keys.
- (6) Cannula (noncollapsible tube to maintain airway).

c. Tape or something to hold the tube in place.

3-9. PROCEDURE

This procedure must be performed within 4 minutes.

a. Place the casualty in the supine position with the neck straight and slightly hyperextended. If you suspect that a casualty has a cervical injury, do not hyperextend the neck. Place a large, rolled-up towel under the casualty's neck or between the shoulder blades so the airway is straight.

b. Locate the cricothyroid space. To do this, palpate the thyroid cartilage (Adam's Apple) with the index finger of one hand. Slide the finger down until you feel the cricothyroid space. (The cricoid cartilage is next).

c. Move the finger upward to the cricothyroid space and cleanse the area. (Cleansing the area may not be possible in a field situation.)

d. Raise a tent of skin overlying the cricothyroid space, using your index finger and thumb.

e. With the cutting instrument in your other hand, make a one and one-half inch horizontal incision through the tented skin down to the cricothyroid space.

f. Reidentify the cricothyroid space by touch and sight.

g. Stabilize the larynx with one hand and make a 1 1/2-inch horizontal incision through the elastic tissues of the cricothyroid membrane.

h. Insert the dilator through the opening.

i. Separate the blades of the dilator to make a larger opening. A rush of air through the opening may be noted.

j. Insert the end of the cannula between the blades of the dilator. The cannula should be in the trachea and directed toward the lungs.

k. Secure the cannula in place to reduce the movement in the opening and to keep the casualty from inhaling the cannula. You may perform mouth to cannula resuscitation if necessary. Inserting the cannula may stimulate reflex coughing. This may aid in clearing the airway, but it is still important to secure the cannula properly.

l. Suction this way. Insert the suction catheter 4 to 5 inches into the cannula. Then, apply suction only when you are withdrawing the catheter. One cc of saline solution may be introduced in the airway to loosen secretions and make suctioning easier. Always allow the casualty to take breaths between efforts to suction.

m. Make a y-shaped cut in a 4" by 4" gauze pad. Place it under the edge of the cannula to prevent irritation to the casualty. (Fold the pad when placing it under the cannula; do not cut the pad at this point.)

n. Place a saline-moistened 4" by 4" gauze pad over the cannula opening to provide moisture in the airway.

Continue with Exercises

EXERCISES, LESSON 3

INSTRUCTIONS. Answer the following exercises by writing the answer in the space provided or by selecting the lettered response that best meets the requirement of the exercise .

After you have completed all of these exercises, turn to "Solutions to Exercises" at the end of the lesson and check your answers. For each exercise answered incorrectly, reread the material referenced with the solution.

1. A cricothyroidotomy can provide a temporary airway between the _____ and the _____ when there is a total airway obstruction.

2. List the five parts of the cricothyroidotomy site.
 - a. _____.
 - b. _____.
 - c. _____.
 - d. _____.

3. List three reasons a person might need a cricothyroidotomy.
 - a. _____.
 - b. _____.
 - c. _____.

4. Signs and symptoms of an obstructed airway include absence of _____, universal _____ signs, and inability to _____.

5. Although a cricothyroidotomy is a relatively safe procedure, complications include bleeding, entering a passage other than the airway, and damaging the _____ and the larynx.

6. The correct position of the casualty is the _____ position when you are going to perform a needle cricothyroidotomy.
7. There is a greater risk when performing a cricothyroidotomy on a person with a large thick neck because of _____.
8. In the procedure of surgical cricothyroidotomy, a dilator is used to _____.
9. In a surgical cricothyroidotomy, the incision made is _____ long.
10. These are the beginning steps in the procedure of performing a needle cricothyroidotomy. The steps are not in the order in which you would do them. Choose the response which lists the steps in the correct order of performance.
 1. Raise a tent of skin overlying the cricothyroid space.
 2. Place the casualty in the correct position.
 3. Locate the cricothyroid space.
 4. Make a horizontal incision cutting down to the cricothyroid space.
 5. Move a finger upward to the cricothyroid space and cleanse the area.
 - a. 3,2,1,5,4.
 - b. 4,1,3,2,5.
 - c. 1,4,2,3,5.
 - d. 1,3,5,1,4.

11. These are steps in the procedure of performing a surgical cricothyroidotomy. The steps are not in the order in which you would do them. Choose the response which lists the steps in the correct order of performance.
1. Stabilize the larynx with one hand and make a 1/2 inch horizontal incision through the elastic tissues of the cricothyroid membrane.
 2. Insert the cannula end between the blades of the dilator.
 3. Insert the dilator, separating its blades to make a larger opening.
 4. Reidentify the cricothyroid space.
 5. Secure the cannula in place.
- a. 1,4,3,2,5.
 - b. 4,1,3,2,5.
 - c. 1,4,2,3,5
 - d. 1,3,5,1,4.

Check Your Answers on Next Page

SOLUTIONS TO EXERCISES, LESSON 3

1. Cricoid cartilage, thyroid cartilage. (para 3-1)
2. Thyroid cartilage.
Cricoid cartilage.
Cricothyroid membrane.
Thyroid gland.
Vocal cords. (para 3-1)
3. Trauma to the larynx.
Foreign bodies/objects obstructing the airway.
Soft tissue involvement (swelling) obstructing the airway. (paras 3-2a, 2b)
4. Respiration, choking, speak at all. (para 3-4)
5. Vocal cords. (para 3-3b)
6. Supine. (para 3-6a)
7. It is difficult to locate the cricothyroid membrane. (para 3-6g CAUTION)
8. Stretch the opening after the incision through the cricothyroid membrane is made. (para 3-8b)
9. 1 1/2 inches. (para 3-9g)
10. c. (para 3-9a through 9e)
11. b. (para 3-9f through 9k)

End of Lesson 3